



Pharmacotherapy Plays Main Role in Managing Acute Epiploic Appendagitis: A Case Report

Touraj Asvadi-Kermani¹, Farnaz Naeimzadeh², Javad Jalili³, Haleh Rezaee^{2*}

¹Department of Surgery, Faculty of Medicine, Tabriz University of Medical Sciences, Tabriz, Iran.

²Department of Clinical Pharmacy, Faculty of Pharmacy, Tabriz University of Medical Sciences, Tabriz, Iran.

³Department of Radiology, Faculty of Medicine, Tabriz University of medical sciences, Tabriz, Iran.

Received: 2020-03-30, Revised: 2020-04-17, Accepted: 2020-04-20, Published: 2020-06-30

ARTICLE INFO

Article type:

Case report

Keywords:

Case Reports;
Epiploic Appendagitis;
Acute Abdomen;
Computed Tomography

ABSTRACT

Epiploic appendagitis is natural fats at the anti-mesenchymal surface of the colon. EP is self-limited. Misdiagnosis can lead to unnecessary hospitalization, antibiotic therapy, and surgical intervention. The incidence reported 8.8 cases / million / year. Here, we report on 36-year-old female patient who presented with acute abdominal pain that was getting worse with the change of position. Based on these symptoms and double contrast computed tomography, she was diagnosed with epiploic appendagitis in adjacent to the sigmoid. The patient was treated successfully with conservative management and antibiotics. Since the signs and symptoms of epiploic appendagitis are nonspecific, but considering of this disease as one of the differential diagnoses of acute abdominal pain can prevent the disease from misdiagnosing.

J Pharm Care 2020; 8(2): 93-95.

► Please cite this paper as:

Asvadi-Kermani T, Naeimzadeh F, Jalili J, Rezaee H. Pharmacotherapy Plays Main Role in Managing Acute Epiploic Appendagitis: A Case Report. J Pharm Care 2020; 8(2): 93-95.

Introduction

Epiploic appendagitis (EP) is one of the rare causes of the acute abdominal pain and therefore not included in the differential diagnosis of acute abdominal pain (1). The exact prevalence of the disease is unknown (2), although an incidence reported 8.8 cases/million/year (3). Unfortunately, most cases are diagnosed with surgery (4). If diagnosed correctly, unnecessary medications such as antibiotics, hospital admission, laboratory testing, dietary restrictions, and unnecessary surgery will be avoided (5, 6). It usually simulates the pain of diseases such as diverticulitis and acute appendicitis. In rare cases, however, it can be confused with cholecystitis (5). The risk factors for this disease are obesity, strenuous exercise, male gender, and losing weight in the short term (2, 7, 8).

This disease can be primary or secondary to appendicitis or diverticulitis (6). The gold standard method of diagnosis is computed tomography (CT), however, if CT is not available ultrasound and magnetic resonance imaging can be used. The EP is visible on CT images only when they are inflamed and/

or surrounded by fluid. In the past, the main treatment for EP was surgery, as they were usually diagnosed after surgery (5, 8, 9). Though some believe in laparoscopic surgery (10), but currently surgical procedures are only available in people who have symptoms or new symptoms despite taking the treatment or developed to abscesses or obstruction (11). The disease is self-limiting (12). Depending on the condition, with conservative treatment, pain is usually reduced within 1 to 4 weeks (13-16). According to the study by Romaniuk et al., (17), colon bacteria may be transmitted to the area and cause peritonitis or abscess. The patient usually has a normal or slightly elevated white blood cell (WBC) count, Erythrocyte sedimentation rate (ESR), and C-reactive protein (CRP) (4). The differential diagnoses are appendicitis, diverticulitis, hernias, and cholecystitis (18).

Case presentation

A 36-year-old female patient with no history of specific disease who had dull pain in the left lower quadrant for three

*Corresponding Author: Dr Haleh Rezaee

Address: Department of Clinical Pharmacy, Faculty of Pharmacy, Tabriz University of Medical Sciences, Tabriz, Iran.

Tel: +984133372250, Fax: +984133344798.

Email: Rezaeeha@tbzmed.ac.ir, Rezaeehale91@gmail.com

weeks before being referred to the physician. During this time, the pain was progressively more severe and localized. The pain was worsening with coughing, activity, and sudden changing in position, getting better at rest and in supine position. On abdominal ultrasound scan uterus, ovaries and kidneys were normal. But due to rebound tenderness and suspicion of diverticulitis CT double contrast was performed and the diagnosis of EP was made. The patient was admitted with a diagnosis of acute abdomen. She denied any associated symptoms such as diarrhea, nausea, vomiting, and bloating. The body temperature was normal. She was hospitalized for 5 days and NPO for the first 48 hours and received intravenous metronidazole 500mg three times daily, intravenous ceftriaxone 1 g twice daily, intramuscular ketorolac 30mg/mL daily. She also received intravenous Ranitidine and subcutaneous heparin for prevention of stress peptic ulcer and deep vein thrombosis, respectively. After discharge, she received ciprofloxacin 500 twice daily, metronidazole 250 three times daily, and naproxen 250 twice daily, orally for a week.

Discussion and Conclusion

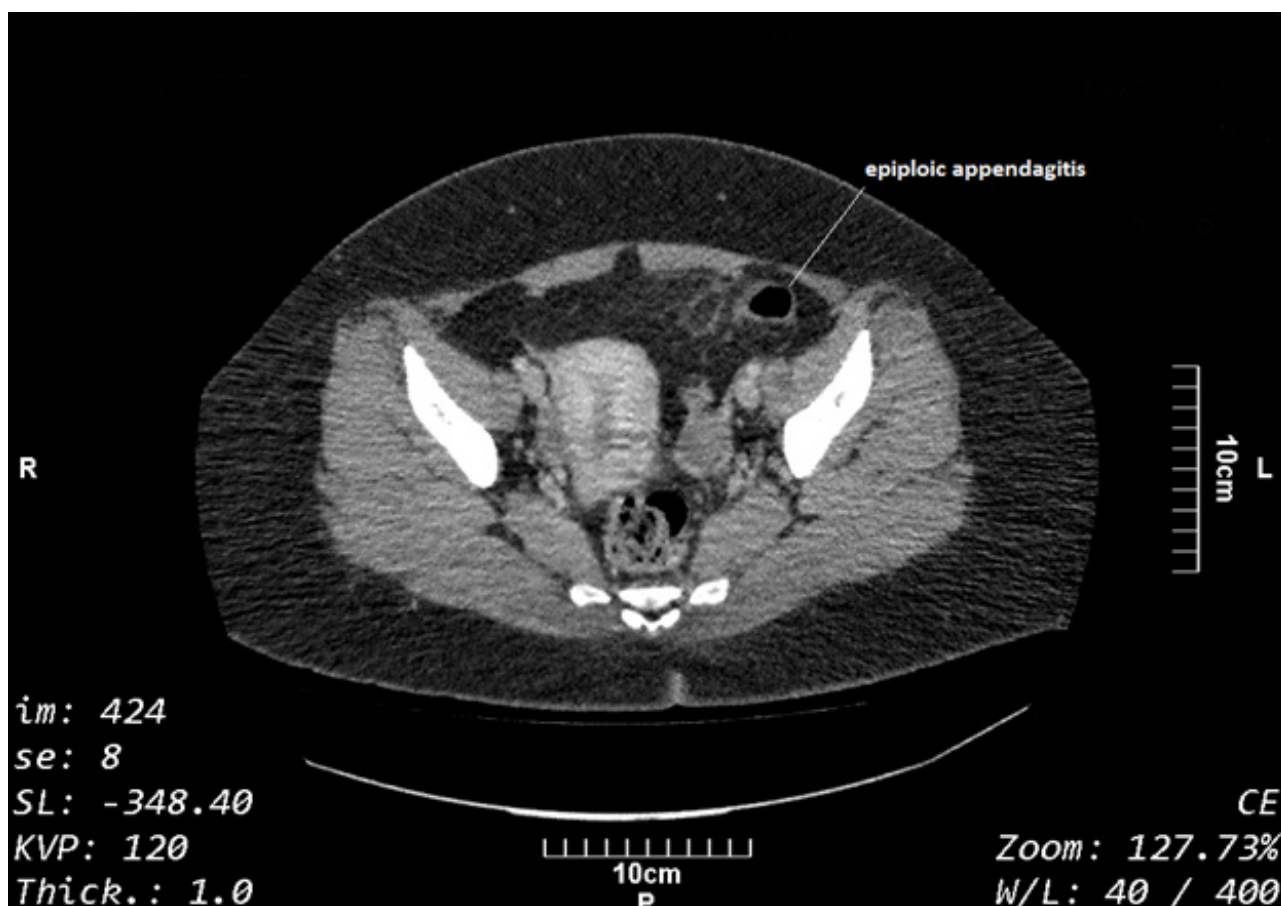
As mentioned, the disease mostly occurs in the fourth

and fifth decades of life in men and its risk factor are obesity, sudden weight loss, and intensive physical activity. The case is presented in this study has been in the fourth decade of her life and has obesity as risk factors.

CRP is usually normal or slightly elevated in patients with EP4. The WBC count, CRP protein, and ESR of the patient were $8.6 \times 10^3 / \text{mm}^3$ (normal range: $4-11 \times 10^3 / \text{mm}^3$), 13 mg/L (normal range: most people without any underlying health problem have a CRP level less than 3 mg/L and nearly always less than 10 mg/L), and 22 mm/hour (normal range: 0-29 mm/hour for women), respectively. Thus, as with other studies, according to laboratory data only CRP was slightly elevated.

EP is typically 0.5 to 5-cm long and 1 cm to 2 cm thick and has no known function. The total number is approximately 100 and generally located along the sigmoid colon (57%) and ileocecum (26%) (19, 20). As the previous studies in this case a hypodense lesion of 25 mm in diameter adjacent to the sigmoid was seen inside the peritoneal fats in the posterior abdominal rectus muscle. Stranding was evident in the fats surrounding the lesion. Thickness of sigmoid wall was normal (Figure 1).

Figure 1. A CT image showing Epiploic appendicitis 2.5 cm in diameter and adjacent to the sigmoid was seen inside the peritoneal fats in the posterior abdominal rectus muscle.



Symptoms of this disease usually decrease within 1-4 weeks with conservative treatment consist of oral nonsteroidal anti-inflammatory drugs (NSAID) and opiates for a short course if pain dose not relief just with NSAIDs (13-16). Patients usually do not need antibiotics, hospitalization, and surgery. Surgery is used only in patients: i) not improved symptoms with conservative treatment ii) with worse previous symptoms iii) addition of new symptoms such as high fever, nausea, and vomiting, etc. iv) with complicated disease, such as abscesses or peritonitis (11).

As the previous cases, this case also experienced a reduction in pain after approximately one week of taking nonsteroidal anti-inflammatory drugs. According to Romaniuk et al., (17), Colonic bacteria enter the area and cause abscesses and peritonitis so antibiotic administration in the short term will have little benefit. According to study of Romaniuk et al., this case was discharged with ciprofloxacin 500 twice daily and metronidazole 250 three times daily orally for one week. Because of the early diagnose of EP in this case, unnecessary interventions such as surgery were avoided. After three months, the patient is symptomatic free.

Since the signs and symptoms of EP are nonspecific and like other causes of acute abdominal pain, the disease usually has not been diagnosed and unnecessary interventions and medications have been imposed on the patient, therefore, if radiologists be aware of this self-limiting disease, can prevent misdiagnosis of this rare disease.

References

- Ross JA. Vascular loops in the appendices epiploicae. Their anatomy and surgical significance, with a review of the surgical pathology of appendices epiploicae. *Br J Surg* 1950;37(148):464-6.
- Schnedl WJ, Krause R, Tafeit E, Tillich M, Lipp RW, Wallner-Liebmann SJ. Insights into epiploic appendagitis. *Nat Rev Gastroenterol Hepatol* 2011;8(1):45-9.
- Gomez M, Besson M, Scotto B, Hutten N, Alison D. Frequency and epidemiology of primary epiploic appendagitis on CT in adults with abdominal pain. *J Radiol* 2008;89(2):235-43.
- Ozdemir S, Gulpinar K, Leventoglu S, et al. Torsion of the primary epiploic appendagitis: a case series and review of the literature. *Am J Surg* 2010;199(4):453-8.
- Legome EL, Belton AL, Murray RE, Rao PM, Novelline RA. Epiploic appendagitis: the emergency department presentation. *J Emerg Med* 2002;22(1):9-13.
- Singh AK, Gervais DA, Hahn PF, Sagar P, Mueller PR, Novelline RA. Acute epiploic appendagitis and its mimics. *Radiographics* 2005;25(6):1521-34.
- Nugent JP, Ouellette HA, O'Leary DP, Khosa F, Nicolaou S, McLaughlin PD. Epiploic appendagitis: 7-year experience and relationship with visceral obesity. *Abdom Radiol* 2018;43(7):1552-7.
- Rioux M, Langis P. Primary epiploic appendagitis: clinical, US, and CT findings in 14 cases. *Radiology* 1994;191(2):523-6.
- Bundred N, Clason A, Eremin O. Torsion of an appendix epiploica of the small bowel. *Br J Clin Pract* 1986;40(9):387.
- Vazquez-Frias J, Castañeda P, Valencia S, Cueto J. Laparoscopic diagnosis and treatment of an acute epiploic appendagitis with torsion and necrosis causing an acute abdomen. *JLS* 2000;4(3):247-50.
- Patel VG, Rao A, Williams R, Srinivasan R, Fortson JK, Weaver WL. Cecal epiploic appendagitis: a diagnostic and therapeutic dilemma. *Am Surg* 2007;73(8):828-30.
- Pines B, Rabinovitch J, Biller SB. Primary torsion and infarction of the appendices zaeiploicae. *Arch Surg* 1941;42(4):775-87.
- Boulanger BR, Barnes S, Bernard AC. Epiploic appendagitis: an emerging diagnosis for general surgeons. *Am Surg* 2002;68(11):1022-5.
- Lien WC, Lai TI, Lin GS, Wang HP, Chen WJ, Cheng TY. Epiploic appendagitis mimicking acute cholecystitis. *Am J Emerg Med* 2004;22(6):507-8.
- Pavone E, Mehta S, Trudel J, Reinhold C, Bret P, Barkun A. Torsion of an appendix epiploica: a nonsurgical cause of acute abdomen. *Dig Dis Sci* 1997;42(4):851-2.
- Uslu NT, Ozgöl E, Oğuz D, Cakir B, Tarhan NC, Coşkun M. An uncommon cause of acute abdomen--epiploic appendagitis: CT findings. *Turk J Gastroenterol* 2007;18(2):107-10.
- Romaniuk C, Simpkins K. Case report: pericolic abscess secondary to torsion of an appendix epiploica. *Clin Radiol* 1993;47(3):216-7.
- Danielson K, Chernin MM, Amberg JR, Goff S, Durham JR. Epiploic appendicitis: CT characteristics. *J Comput Assist Tomogr* 1986;10(1):142-3.
- Legome EL, Sims C, Rao PM. Epiploic appendagitis: adding to the differential of acute abdominal pain. *J Emerg Med* 1999;17(5):823-6.
- Sangha S, Soto JA, Becker JM, Farraye FA. Primary Epiploic Appendagitis: An Underappreciated Diagnosis. A Case Series and Review of the Literature. *Dig Dis Sci* 2004;49(2):347-50.